

# Orbitofrontal volume deficit in schizophrenia and thought disorder

Motoaki Nakamura,<sup>1,2</sup> Paul G. Nestor,<sup>1,3</sup> James J. Levitt,<sup>1,2</sup> Adam S. Cohen,<sup>2</sup> Toshiro Kawashima,<sup>1,2</sup> Martha E. Shenton<sup>1,2</sup> and Robert W. McCarley<sup>1</sup>

<sup>1</sup>Clinical Neuroscience Division, Laboratory of Neuroscience, Department of Psychiatry, Veterans Affairs Boston Healthcare System, Brockton Division, Brockton, MA and Harvard Medical School, <sup>2</sup>Psychiatry Neuroimaging Laboratory, Department of Psychiatry, Brigham and Women's Hospital, Harvard Medical School and <sup>3</sup>Department of Psychology, University of Massachusetts, Boston, MA, USA

Correspondence to: Dr Robert W. McCarley, Department of Psychiatry (116A), VA Boston Healthcare System, Brockton Division, Harvard Medical School, 940 Belmont St., Brockton, MA 02301, USA  
E-mail: robert.mccarley@hms.harvard.edu

**Orbitofrontal Cortex (OFC) structural abnormality in schizophrenia has not been well characterized, probably due to marked anatomical variability and lack of consistent definitions. We previously reported OFC sulcogyral pattern alteration and its associations with social disturbance in schizophrenia, but OFC volume associations with psychopathology and cognition have not been investigated. We compared chronically treated schizophrenia patients with healthy control (HC) subjects, using a novel, reliable parcellation of OFC subregions and their association with cognition, especially the Iowa Gambling Task (IGT), and with schizophrenic psychopathology including thought disorder. Twenty-four patients with schizophrenia and 25 age-matched HC subjects underwent MRI. OFC Regions of Interest (ROI) were manually delineated according to anatomical boundaries: Gyrus Rectus (GR); Middle Orbital Gyrus (MiOG); and Lateral Orbital Gyrus (LOG). The OFC sulcogyral pattern was also classified. Additionally, MiOG probability maps were created and compared between groups in a voxel-wise manner. Both groups underwent cognitive evaluations using the IGT, Wisconsin Card Sorting Test, and Trail Making Test (TMT). An 11% bilaterally smaller MiOG volume was observed in schizophrenia, compared with HC ( $F_{1,47} = 17.4$ ,  $P = 0.0001$ ). GR and LOG did not differ, although GR showed a rightward asymmetry in both groups ( $F_{1,47} = 19.2$ ,  $P < 0.0001$ ). The smaller MiOG volume was independent of the OFC sulcogyral pattern, which differed in schizophrenia and HC ( $\chi^2 = 12.49$ ,  $P = 0.002$ ). A comparison of MiOG probability maps suggested that the anterior heteromodal region was more affected in the schizophrenia group than the posterior paralimbic region. In the schizophrenia group, a smaller left MiOG was strongly associated with worse 'positive formal thought disorder' ( $r = -0.638$ ,  $P = 0.001$ ), and a smaller right MiOG with a longer duration of the illness ( $r = -0.618$ ,  $P = 0.002$ ). While schizophrenics showed poorer performance than HC in the IGT, performance was not correlated with OFC volume. However, within the HC group, the larger the right hemisphere MiOG volume, the better the performance in the IGT ( $r = 0.541$ ,  $P = 0.005$ ), and the larger the left hemisphere volume, the faster the switching attention performance for the TMT, Trails B ( $r = -0.608$ ,  $P = 0.003$ ). The present study, applying a new anatomical parcellation method, demonstrated a subregion-specific OFC grey matter volume deficit in patients with schizophrenia, which was independent of OFC sulcogyral pattern. This volume deficit was associated with a longer duration of illness and greater formal thought disorder. In HC the finding of a quantitative association between OFC volume and IGT performance constitutes, to our knowledge, the first report of this association.**

**Keywords:** schizophrenia; orbitofrontal region; thought disorder; decision making; Iowa gambling task

**Abbreviations:** ANOVA = analysis of variance; GR = Gyrus Rectus; ICC = intracranial contents; IGT = Iowa Gambling Task; IQ = intelligence quotient; LOG = Lateral Orbital Gyrus; MiOG = Middle Orbital Gyrus; OFC = orbitofrontal cortex; TMT = Trail Making Test; WAIS-III = Wechsler adult intelligence scale, 3rd edition; WCST = Wisconsin card sorting test.

Received May 15, 2007. Revised September 29, 2007. Accepted October 9, 2007. Advance Access publication December 3, 2007

## Introduction

The human Orbitofrontal Cortex (OFC), a major part of the social brain, is characterized by enormous inter-individual variability in its sulcogyral morphology (Ono *et al.*, 1990; Chiavaras and Petrides, 2000; Nakamura *et al.*, 2007), which could reflect neurodevelopmental features of neuronal migration, local neuronal connection, synaptic development, lamination and formation of cytoarchitecture (Rakic, 1988; Armstrong *et al.*, 1995). Another notable feature in the OFC region is the cytoarchitectural gradient in anterior-posterior axis: from anterior (rostral) granular region (six cortical layers) to transitional dysgranular region (four cortical layers) and posterior (caudal) agranular region (three cortical layers) (Beck, 1949; Barbas and Pandya, 1989; Ongur *et al.*, 2003). According to Mesulam's classification of human cerebral cortex, rostral and caudal OFC regions are classified as heteromodal and paralimbic regions, respectively (Mesulam, 1985). The human OFC is located between the frontopolar gyri rostrally, the anterior perforated substance caudally, the inferior frontal gyrus laterally and the ventromedial margin of the cerebral hemisphere medially (Duvernoy, 1999; Chiavaras and Petrides, 2000). In addition to intrinsic corticocortical connections within ventromedial prefrontal cortex (Carmichael and Price, 1996), the OFC has extensive neuronal connections with other cortical areas, including primary sensory cortices (sensory inputs) and all limbic/paralimbic regions, and with subcortical structures of the mediodorsal nucleus of the thalamus (magnocellular portion), ventromedial striatum, hypothalamus and midbrain (Fuster, 1997; Ongur and Price, 2000).

Functionally, the human OFC is thought to be involved in sensory-visceromotor multimodal integration (Ongur and Price, 2000), affective evaluation of reinforcers (rewards and punishers), expectation, motivation, decision-making and goal-directed behaviour (Gottfried *et al.*, 2003; Holland and Gallagher, 2004; Walton *et al.*, 2004). Based on previous human neuroimaging and neuropsychological studies, Kringelbach (2005) proposed a functional model of human OFC which was characterized by functional dissociations of medial-lateral and posterior-anterior OFC regions. According to the model, the medial OFC region is associated with monitoring, learning and memory of reward value of reinforcers, while the lateral OFC region is associated with evaluation of punishers and response inhibition. In terms of the posterior-anterior dissociation, the anterior OFC region is related to more complex or abstract reinforcers such as monetary gain and loss than to primary reinforcers such as food.

The social deficit consequences of large orbitofrontal lesions have long been known (Harlow, 1848), although the quantitative association of more subtle anatomical deficits or anomalies of OFC with social behaviour has not been well characterized. We hypothesized that the OFC would show abnormalities in schizophrenia, a socially disabling

disorder, and one associated with altered emotional and cognitive states. In schizophrenia, basic sensory integration, thought processes, emotional processing and social communication are all often markedly disturbed, possibly reflected in clinical phenomena. Moreover, recent data linking OFC to semantic processing-related language areas (Duffau *et al.*, 2005; Mandonnet *et al.*, 2007) suggested the possibility that OFC abnormalities might be related to schizophrenic thought disorder, an association hitherto uninvestigated but congruent with lesion data (Schnider, 2003).

Previous findings in OFC volumetry have been quite inconsistent, some reporting smaller OFC volume in schizophrenia (Gur *et al.*, 2000; Convit *et al.*, 2001), some reporting even larger OFC volume in first-episode schizophrenia (Szeszko *et al.*, 1999; Lacerda *et al.*, 2007), and others reporting no difference with healthy controls (HCs) (Baare *et al.*, 1999; Chemerinski *et al.*, 2002; Rupp *et al.*, 2005; Sapara *et al.*, 2007). In terms of gender-specific findings, Gur *et al.* (2000) reported that orbitofrontal grey matter volume was smaller only in female patients with schizophrenia but not in male patients. A meta-analysis of recent Voxel-Based Morphometry (VBM) studies in schizophrenia (Honea *et al.*, 2005) showed medial orbital gyrus and gyrus rectus were reported to be abnormal in about 20% of the 15 cross-sectional VBM studies, a relatively small percentage compared with the more than 50% of studies finding volume deficits in left superior and medial temporal gyri. This inconsistency of findings likely results from the high structural variability in OFC region across individuals, making for large variances in VBM studies, as well as making consistent ROI definitions difficult (Lacerda *et al.*, 2003).

In terms of the genetic relationship between OFC structure and schizophrenia, a twin study using VBM reported that, in twin-pairs discordant for schizophrenia, the schizophrenic twin showed a grey matter density decrease in the left medial OFC as compared to the healthy twin, possibly reflecting an increased genetic risk to develop schizophrenia (Hulshoff Pol *et al.*, 2006). Another VBM study demonstrated that Pericentriolar Material 1 (PCM1) gene, located on chromosome 8p22, was associated with OFC grey matter volumetric deficits, possibly implying a susceptibility to schizophrenia (Gurling *et al.*, 2006).

Since the OFC has high inter-individual structural variability and is heterogeneous anatomically and also functionally, we concluded it was more appropriate to evaluate each OFC subregion separately rather than the OFC region as a whole. Based on cytoarchitectural findings, Ongur *et al.* (2003) proposed a subdivision of the human OFC into area 11 (anterior part), area 13 (posterior part), area 47/12 (lateral part) and area 14 (medial part). As *in vivo* neuroimaging cannot differentiate relatively subtle cytoarchitectural differences, such as paralimbic *vs.* heteromodal cortex, utilization of sulcal boundaries appears

**Table 1** Demographic and clinical characteristics of study groups

Variable	Mean (SD) [Range]		df <sup>a</sup>	t-test	P-value
	Schizophrenic patients <i>n</i> = 24	Healthy control subjects <i>n</i> = 25			
Age (year)	39.1 (10.3) [20–57]	41.1 (9.1) [22–55]	1, 47	0.71	0.48
Gender (male/female)	24/0	19/6			
Handedness <sup>b</sup>	0.75 (0.25) [0.1–1.0]	0.76 (0.22) [0.1–1.0]	1, 47	0.15	0.89
Socioeconomic Status <sup>c</sup>	3.8 (1.2)	2.4 (1.1)	1, 46	4.03	
subject's own					0.0002**
parental	2.8 (1.1)	2.7 (1.3)	1, 45	0.34	0.74
Education (school year)	12.8 (1.8)	15.0 (2.0)	1, 46	4.01	0.0002**
WAIS-III Verbal IQ	95.4 (14.8)	104.2 (14.2)	1, 44	2.08	0.04*
WAIS-III Performance IQ	88.9 (12.2)	105.3 (18.1)	1, 44	3.61	0.001**
Symptom Onset (years)	22.5 (4.7), <i>n</i> = 23	NA			
Duration of Illness (years)	16.0 (10.3), <i>n</i> = 22	NA			
Antipsychotic Medication dosage <sup>d</sup>	436.1 (369.6), <i>n</i> = 21	NA			
PANSS (total score)	81.3 (26.5), <i>n</i> = 24	NA			

WAIS-III = Wechsler Adult Intelligence Scale- 3rd Edition (Wechsler, 1997); IQ = Intelligence quotient; PANSS = Positive and Negative Syndrome Scale (Kay et al., 1987); NA = data not applicable.

<sup>a</sup>The df differ among variables owing to unavailability of data in some participants. <sup>b</sup>Handedness was evaluated using the Edinburgh inventory and right-handedness is above zero. <sup>c</sup>Higher scores indicate lower socioeconomic status (Hollingshead, 1965).

<sup>d</sup>Chlorpromazine equivalent (mg).

\**P* < 0.05, \*\**P* < 0.01.

necessary for defining OFC subdivisions in MRI studies, although sulcal boundaries do not always coincide with cytoarchitectural boundaries. Using the major orbital sulci (Duvernoy, 1999), the OFC region can be divided into five subregions of gyrus rectus, and medial, anterior, posterior and lateral orbital gyri. To mitigate differences arising from variability of OFC sulcogyral morphology, especially the H-shaped sulcus (Chiavaras and Petrides, 2000), we also evaluated the possibility of association between OFC region of interest (ROI) volumes and sulcogyral pattern, previously found by us to be different for schizophrenia and HCs (Nakamura et al., 2007).

Given the OFC variability, we thought it useful to increase reliability of parcellation by a novel ROI definition of OFC subregions using 3-D MRI and sulcal variability information. We noticed that olfactory sulcus and lateral orbital sulcus were less variable sulci than all other orbital sulci. Thus, to control sulcogyral pattern variation in the H-shaped sulcus, we selected the two stable sulci to be sulcal boundaries, dividing OFC into three ROI of Gyrus Rectus (GR), Middle Orbital Gyrus (MiOG) and Lateral Orbital Gyrus (LOG). Finding this approach reliable, we then compared schizophrenic and HC groups. Additionally, to investigate the association of OFC ROI volumes with performance in the evaluation of abstract reinforcers and the subsequent decision-making process, we administered the Iowa Gambling Task (IGT) to both groups. The Wisconsin Card Sorting Test (WCST) and the Trail Making Test (TMT) were also administered to examine regional specificity of functional association with the OFC ROI volumes.

## Methods

### Subjects

Twenty-four patients with chronic schizophrenia and 25 HC subjects participated in this study. Table 1 shows demographic and clinical characteristics of the study groups. All patients were diagnosed with schizophrenia based on the DSM-IV criteria, using information from the Structured Clinical Interview for DSM-III-R (Spitzer et al., 1990b) by trained interviewers (MES, PGN). Patients were recruited from the VA Boston Healthcare System, Brockton Division. All patients were receiving antipsychotic medication, with a mean daily dose equivalent to 436.1 mg of chlorpromazine (Woods, 2003) (typical antipsychotics, 20.0%, atypical antipsychotics, 70.0%, both, 10.0%). Patient mean age was 39.1 ± 10.3 years, mean age at symptom onset was 22.5 ± 4.7 years, and mean duration of illness was 16.0 ± 10.3 years, defined as elapsed years from the first hospitalization for psychosis. HC subjects were recruited through newspaper advertisements and screened using the Structured Clinical Interview (SCID non-patient edition) (Spitzer et al., 1990a) by the same trained interviewers. No control subjects had an Axis I psychiatric disorder or a first-degree relative with an Axis I psychiatric disorder.

Handedness was assessed using the Edinburgh inventory (Oldfield, 1971). Subjects' own and parental Socioeconomic status (SES) were measured by the Hollingshead two-factor index (1 = best, 5 = poorest) (Hollingshead, 1965), which consists of educational and occupational scores. Subjects from both groups were evaluated using the Wechsler Adult Intelligence Scale (WAIS-III) (Wechsler, 1997); the WCST (Heaton, 1981), a measure requiring concept formation, abstraction and mental flexibility, the TMT (Reitan, 1958), a measure of visuomotor processing speed, and the IGT (Bechara et al., 1994), a measure of affective evaluation of reinforcers (money gain or loss),

expectation, decision-making and goal-directed behaviour (described in detail later). A lesion study has indicated the IGT reflects functions mediated by OFC and medial PFC independently of dorsolateral PFC-mediated functions (Bechara *et al.*, 1998). In addition, the dorsolateral PFC has been primarily related to WCST and TMT performance (Cummings, 1993). We thus used this suite of three tests to determine if a regionally specific pattern of functional association with OFC ROI volumes could be found.

Both groups were matched in terms of age at MRI scan ( $P=0.48$ ), Parental Socioeconomic Status (PSES,  $P=0.74$ ), and handedness ( $P=0.89$ ) (all right-handed). The patient group consisted of only males, while the control group had 19 males and 6 females. Volumetric findings were not changed when the six female controls were excluded from the analysis. Patients had poorer SES (SES,  $P=0.0002$ ) and less education ( $P=0.0002$ ) and lower IQ (verbal IQ:  $P=0.04$ , performance IQ:  $P=0.001$ ) than controls, reflecting the debilitating effects of psychosis.

The Positive and Negative Syndrome Scale (PANSS) (Kay *et al.*, 1987), the Scale for the Assessment of Positive Symptoms (SAPS) (Andreasen, 1984), and the Scale for the Assessment of Negative Symptoms (SANS) (Andreasen, 1981) were administered to patients in order to evaluate clinical symptomatology. Of note, SAPS items for positive formal thought disorder include the following eight items 'derailment', 'tangentiality', 'incoherence', 'illogicality', 'circumstantiality', 'pressure of speech', 'distractive speech' and 'clanging'.

Most of the clinical and neuropsychological evaluation was performed at protocol entrance, with MRI scans occurring ~1 week later. The IGT was administered a median of 9.3 months after the MRI scan, as the IGT was begun later.

This study was approved by the VA Boston Healthcare System and Harvard Medical School Institutional Review Boards. Written informed consent was obtained from all subjects prior to study participation.

## MRI processing

MR images were acquired with a 1.5-Tesla General Electric scanner (GE Medical Systems, Milwaukee) at the Brigham and Women's Hospital in Boston. A three-dimensional Fourier transformed spoiled gradient-recalled (SPGR) acquisition sequence yielded a coronal series of contiguous 1.5 mm images (TE = 5 msec, TR = 35 msec, repetition = 1, nutation angle = 45°, field of view = 24 cm, acquisition matrix = 256 × 256 × 124, voxel dimension = 0.9375 × 0.9375 × 1.5 mm). Next, a double-echo spin-echo yielded 108 contiguous axial double-echo (proton-density- and T<sub>2</sub>-weighted) slices, with 54 levels, throughout the brain (TE = 30 and 80 msec, TR = 3000 msec, field of view = 24 cm, an interleaved acquisition with 3-mm slice thickness, voxel dimensions = 0.9375 × 0.9375 × 3.0 mm). The T<sub>2</sub> information from the double-echo spin-echo axial slices was registered to the SPGR images. An expectation-maximization (EM) segmentation technique (Bouix *et al.*, 2007; Pohl *et al.*, 2007) was used to segment the images into three major tissue classes: grey matter; white matter and CSF, using both SPGR and T<sub>2</sub>-weighted MR information as well as spatial priors. This technique was used to get Intra-Cranial Contents (ICC) volume. Manual tracing of OFC ROI was performed on non-segmented images to avoid segmentation errors due to susceptibility artefacts, which are common in this OFC region.

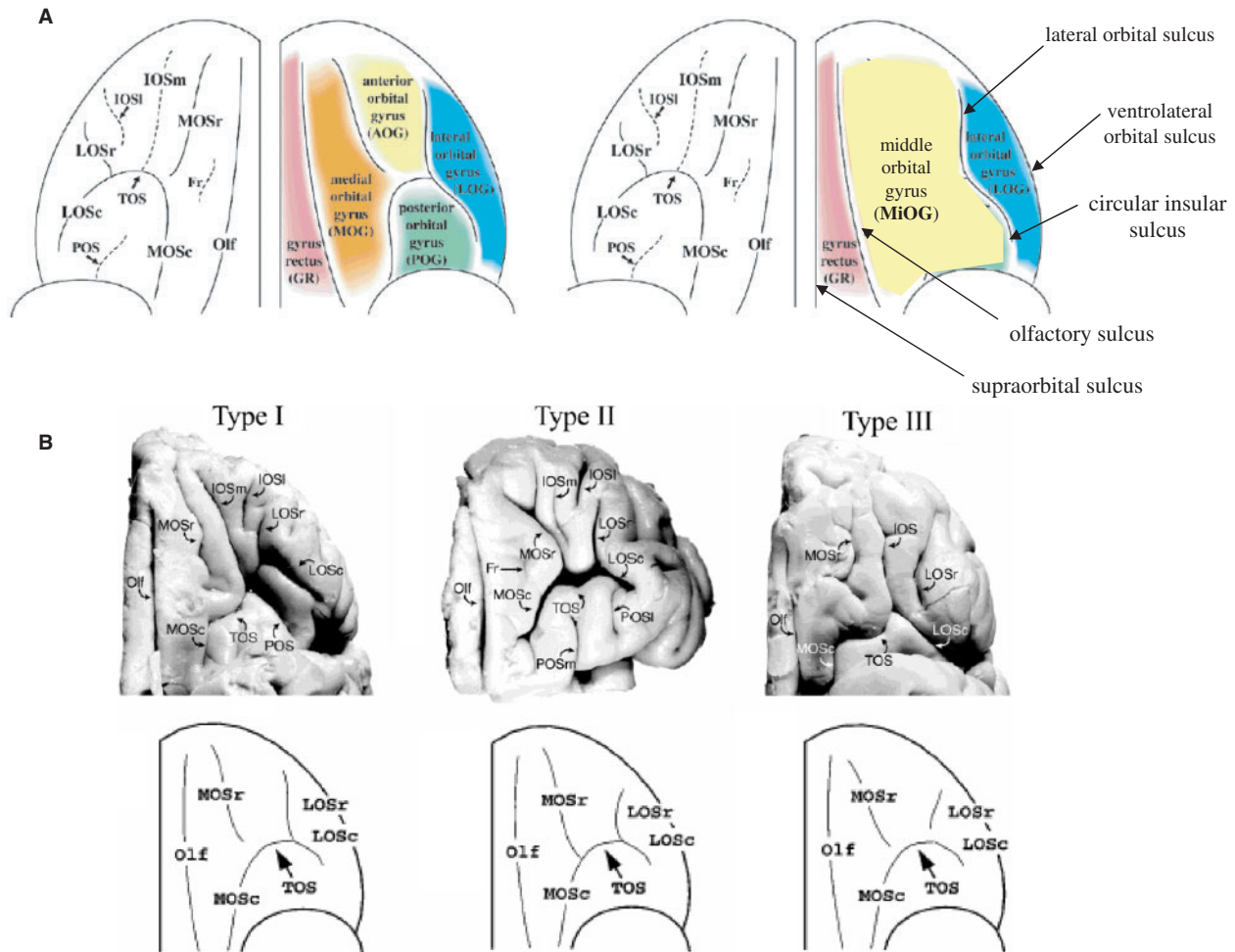
Images were realigned using the line between the anterior and posterior commissures and the sagittal sulcus to correct head tilt, and resampled into isotropic voxels (0.9375 mm<sup>3</sup>). This realignment procedure was essential for precise and consistent ROI delineation. Three-dimensional information was used to provide reliable delineation of the OFC ROI with a software package for medical image analysis (3D slicer, <http://www.slicer.org>) on a workstation.

## IGT

The IGT (Bechara *et al.*, 1994) was administered using a computerized version (Rodriguez-Sanchez *et al.*, 2005). Subject faced a computer screen where four decks of cards were shown (A, B, C and D). Subjects were asked to choose cards from the decks. When subjects clicked on a deck, the computer screen notified the subjects of the amount of money gained or lost—the task goal is to win as much money as possible. Subjects did not know that they would choose a total of 100 cards. Nor did subjects know that there are two advantageous decks, C and D, for which little money is won on a single choice but even less is lost (resulting in a net gain) and two disadvantageous decks, A and B, for which a lot of money is won but even more is lost (resulting in a net loss). In other words, the absolute magnitude of the award is large in the A and B decks, but money loss (punishment) occurs more frequently. In contrast, in the C and D decks, the absolute magnitude of the award is small but money gain (reward) occurs more frequently. The key to success in this gambling task is to eliminate the amount of money lost rather than to obtain a jackpot. The variable that measures total performance on this task was the difference between choices in advantageous decks minus choices in disadvantageous decks for the whole task [(C+D) – (A+B)]. We termed this variable the gambling score, with a higher score reflecting a better performance. To assess subjects' ability to acquire a strategy how to reduce money loss, we examined the gambling score during the last period of 20 trials (trials 81 to 100, when any developed strategy would have been most evident) as well as total gambling score (trials 1 to 100, thus including earlier trials where any strategy was being developed) (Bechara *et al.*, 2000). To estimate performance in the evaluation of abstract reinforcers (money gain and loss) and the subsequent decision-making process and goal-directed behaviour, we used not only the gambling score, but also the total amount of money lost, and the total amount of money earned [(total amount won) – (total amount lost)] were calculated and compared between the groups. To evaluate subject performance over time on task, five periods of consecutive 20 computer-recorded choices were separately analysed, in addition to an analysis of the whole.

## Sulcogyral pattern identification

Details of identification are described elsewhere (Nakamura *et al.*, 2007), and were based on previous work by Chiavaras and Petrides (2000), which classified the OFC sulcogyral pattern into three types (Type I, Type II, Type III, in order of frequency) in each hemisphere (see Fig. 1). In Type I, rostral and caudal portions of the Lateral Orbital Sulcus (LOS) were connected, while the Medial Orbital Sulcus (MOS) were clearly interrupted between rostral and caudal portions of MOS. In Type II, rostral and caudal portions of both the MOS and LOS were connected, and continuous MOS and LOS were jointed by the horizontally oriented Transverse Orbital Sulcus (TOS). In Type III, rostral and



**Fig. 1** Orbitofrontal subregions and sulcogyral pattern. **(A)** Orbitofrontal subregions defined by sulci. The Middle Orbital Gyrus (MiOG) defined by us is located between olfactory sulcus medially and lateral orbital sulcus and circular insular sulcus laterally. **(B)** Sulcogyral pattern within orbitofrontal region. Type I expression is the most frequent and Type III expression is the least frequent. Abbreviations: GR = Gyrus Rectus; MiOG = Middle Orbital Gyri; LOG = Lateral Orbital Gyrus; Olf = olfactory sulcus; MOS = medial orbital sulcus (-r: rostral, -c: caudal); TOS = transverse orbital sulcus; LOS = lateral orbital sulcus (-r: rostral, -c: caudal); IOS = intermediate orbital sulcus (-m: medial, -l: lateral); POS = posterior orbital sulcus; Fr = sulcus fragmentosus. Figures were adapted and modified from a previous paper by Chiavaras and Petrides (see M.M. Chiavaras and M. Petrides. Orbitofrontal sulci of the human and macaque monkey brain. *J Comp Neurol* 2000; 422: 35–54; reprinted with permission of Wiley-Liss, Inc., a subsidiary of John Wiley & Sons, Inc.).

caudal portions of both MOS and LOS were interrupted. Group comparison in the sulcogyral pattern was performed by Chi-square test.

### ROI definition of orbitofrontal gyri

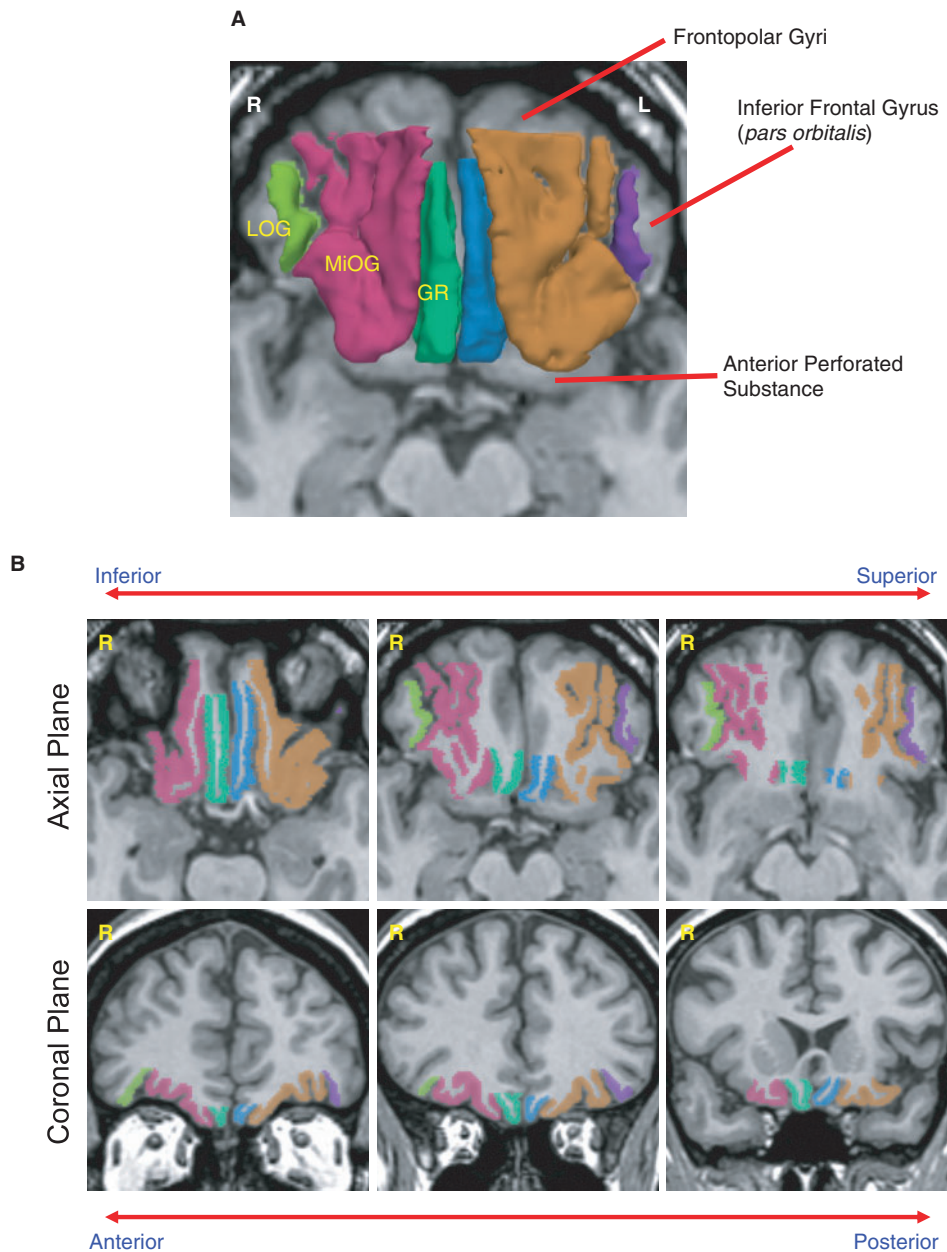
Figures 1A and 2 show the delineation of the left and right GR, the (MiOG and the LOG. In Table 2, each boundary definition is summarized. More detailed information on the OFC ROI definition with detailed figures and comments on anatomical and definitional issues is available as supplementary material online.

All manual delineations were performed by M.N., who was blind to subject group. For assessing interrater reliability, three raters (M.N., A.C. and T.K.), also blind to subject diagnosis, independently delineated left and right GR, MiOG and LOG for seven randomly selected cases. The intraclass correlation

coefficients were 0.95 (left GR), 0.96 (right GR), 0.99 (left MiOG), 0.96 (right MiOG), 0.96 (left LOG) and 0.99 (right LOG).

### Statistical analysis

Independent-samples *t*-tests were performed to assess group differences in demographic data, including age, SES, PSES and handedness. To evaluate group difference in OFC volume, a mixed model Analysis of Variance (ANOVA) was applied to relative volume (%), with diagnostic group as the between-subjects factor, and within-subjects factors of hemisphere and OFC subregion. The ICC was derived from the EM atlas segmentation, and included all grey matter, white matter and CSF volumes above the most inferior axial slice containing cerebellum. The ICC was used to calculate the relative volume [(absolute volume/ICC) × 100], controlling for individual head size. The groups did not differ significantly in ICC ( $P=0.86$ ).



**Fig. 2** MR Images of three orbitofrontal subregions. **(A)** 3D reconstruction of the three orbitofrontal subregion ROI superimposed on axial SPGR image: Gyrus Rectus (GR; left: blue, right: green); Middle Orbital Gyri (MiOG; left: brown, right: red); and Lateral Orbital Gyrus (LOG; left: purple, right: light green). **(B)** Orbitofrontal ROIs in axial and coronal planes of SPGR images. Color coding as in (A). See method section for their boundary definition.

Pearson's correlations evaluated associations of OFC relative volumes with demographic, clinical and cognitive measures within each group. To control for inflation of Type I error in calculating multiple univariate correlations, we applied a more conservative alpha of .01 (two-tailed) to report significance.

### MiOG probability map

Since we combined medial, anterior and posterior orbital gyri into a single ROI of MiOG due to the H-shaped sulcus' enormous variability, to provide more precise localization of any subregion differences we created probability maps of MiOG from

manually-drawn ROIs, and compared the groups using optimized VBM methodology (Ashburner and Friston, 2000; Good *et al.*, 2001). Initially, manually drawn MiOG ROIs were bilaterally smoothed by an isotropic Gaussian kernel with 12 mm full-width half maximum to create MiOG probability maps. Second, realigned SPGR images of all subjects were spatially normalized and then averaged to create a study-specific template. Subsequently, each SPGR image was non-linearly transformed into the customized template. Third, the same transformation was applied to each corresponding MiOG probability map one by one. Finally, spatially normalized MiOG maps were modulated by the Jacobian determinant and then statistically compared between the groups

**Table 2** Boundary definition (in the coronal plane)

ROI	Boundary	Description (in the coronal plane)
Gyrus Rectus (GR)	Anterior	The most anterior slice where olfactory sulcus can be seen clearly.
	Posterior	GR disappears before olfactory trigone and subcallosal gyrus appear.
	Lateral	Olfactory sulcus.
	Medial (Superior)	The most superior boundary point between GR and MiOG (mostly, supraorbital sulcus).
Middle Orbital Gyrus (MiOG)	Anterior	One slice posterior to the slice at one fourth anterior point between the most anterior slice of brain parenchyma and the most anterior slice where corpus callosum are separately seen above and below the septum. MiOG disappears at the level of anterior perforated substance.
	Posterior	
	Lateral (i) anterior	Lateral orbital sulcus (lateral ramus of H-shaped sulcus).
	(ii) transitional	Transitional part (up to 4~5 slices) between anterior and posterior portions.
	(iii) posterior	Circular insular sulcus.
Lateral Orbital Gyrus (LOG)	Medial	Olfactory sulcus.
	Anterior	The most anterior slice where both of lateral orbital sulcus and ventrolateral orbital sulcus can be seen clearly.
	Posterior	The most posterior slice where lateral orbital sulcus can be seen clearly.
	Lateral	Ventrolateral orbital sulcus.
	Medial	Lateral orbital sulcus.

with ICC values as a nuisance variable. Uncorrected  $P < 0.001$  was considered significant in this group comparison.

## Results

### Volume comparison

Table 3 provides descriptive results of each OFC volume and results of independent-samples  $t$ -tests. Figure 3 shows scatterplots of volumetric variables.

ANOVA showed a main effect of group ( $F_{1,47} = 11.34$ ,  $P = 0.002$ ) and subregion  $\times$  group interaction ( $F_{2,47} = 13.52$ ,  $P < 0.0001$ ). In terms of left-right asymmetry, hemisphere  $\times$  subregion interaction was significant ( $F_{2,47} = 13.70$ ,  $P < 0.0001$ ), but there was no hemisphere  $\times$  group interaction ( $F_{1,47} < 0.0001$ ,  $P > 0.99$ ). Follow-up two-factor ANOVA was then performed within each subregion (GR, MiOG, LOG).

GR did not differ between the groups ( $F_{1,47} = 0.28$ ,  $P = 0.60$ ), although the main effect of hemisphere was significant ( $F_{1,47} = 19.18$ ,  $P < 0.0001$ ), indicating right  $>$  left asymmetry of GR across the groups. MiOG differed between the groups ( $F_{1,47} = 17.40$ ,  $P = 0.0001$ ) without hemisphere  $\times$  group interaction ( $F_{1,47} = 0.08$ ,  $P = 0.77$ ), indicating that MiOG was bilaterally smaller in the schizophrenia group. LOG did not differ between the groups ( $F_{1,47} = 0.19$ ,  $P = 0.67$ ).

In summary, the schizophrenia group showed smaller OFC volume specifically in bilateral MiOG compared to the HC group (11% difference). Group comparison results reported here remained the same when analysing absolute volume ( $\text{cm}^3$ ) with ICC as a covariate.

### Sulcogyral pattern and volume

Association between sulcogyral pattern (Type I/II/III) of 'H-shaped' sulcus and MiOG volume was examined because MiOG ROI was defined by the 'H-shaped' and olfactory sulci (Fig. 1). Consistent with our previous report (Nakamura *et al.*, 2007), distribution of 'H-shaped' sulcogyral pattern was quite different between the groups ( $\chi^2 = 12.49$ ,  $P = 0.002$ ) within the present dataset; the most frequent, Type I expression, was decreased, and the rarest, Type III expression, was increased in the schizophrenia group (schizophrenia: Type I = 43.8%, Type II = 31.3%, Type III = 25.0%, HC: Type I = 58.0%, Type II = 32.0%, Type III = 10.0%). Within each group, one-way ANOVA was applied to MiOG relative volume with the sulcogyral pattern (Type I/II/III) as a factor. Main effect of the sulcogyral pattern was not observed within the schizophrenia group ( $F_{2,47} = 1.28$ ,  $P = 0.29$ ) and also not within the HC group ( $F_{2,49} = 0.13$ ,  $P = 0.88$ ), suggesting that the MiOG volume difference observed in the present study was not affected by the sulcogyral pattern difference (Fig. 4). Additionally, categorical regression analyses also did not show any effect of sulcogyral pattern on MiOG volume. However, the normal rightward asymmetry of GR volume observed in both groups disappeared in patients with Type III expression ( $F_{2,47} = 4.15$ ,  $P = 0.022$ ). The asymmetry index was calculated as follows:  $2 \times [(\text{left GR volume}) - (\text{right GR volume})] / [(\text{left GR volume}) + (\text{right GR volume})]$  for this analysis. Additionally, patients with Type III had smaller ICC volume compared to patients without Type III ( $t_{22} = 2.12$ ,  $P = 0.045$ ), consistent with our previous study (Nakamura *et al.*, 2007).

**Table 3** Descriptive data and independent-samples *t*-test

Volume	Group	Descriptive data		t-test		
		Mean	SD	<i>t</i> (47)	<i>P</i>	
Intracranial contents (ICC; cm <sup>3</sup> )	SZ ( <i>n</i> = 24)	1440.07	113.64	0.18	0.86	
	HC ( <i>n</i> = 25)	1445.60	104.74			
Absolute volume; cm <sup>3</sup>						
Gyrus Rectus (GR)	Left	SZ ( <i>n</i> = 24)	2.30	0.38	0.18	0.86
		HC ( <i>n</i> = 25)	2.32	0.40		
	Right	SZ ( <i>n</i> = 24)	2.42	0.47	0.85	0.40
		HC ( <i>n</i> = 25)	2.53	0.43		
Middle Orbital Gyrus (MiOG)	Left	SZ ( <i>n</i> = 24)	6.71	0.74	3.45	0.0012**
		HC ( <i>n</i> = 25)	7.50	0.85		
	Right	SZ ( <i>n</i> = 24)	6.40	0.74	3.04	0.0038**
		HC ( <i>n</i> = 25)	7.16	0.98		
Lateral Orbital Gyrus (LOG)	Left	SZ ( <i>n</i> = 24)	0.72	0.21	0.01	1.00
		HC ( <i>n</i> = 25)	0.72	0.19		
	Right	SZ ( <i>n</i> = 24)	0.81	0.18	0.65	0.52
		HC ( <i>n</i> = 25)	0.78	0.18		
Relative volume; %						
Gyrus Rectus (GR)	Left	SZ ( <i>n</i> = 24)	0.160	0.025	0.08	0.93
		HC ( <i>n</i> = 25)	0.161	0.026		
	Right	SZ ( <i>n</i> = 24)	0.168	0.028	0.90	0.37
		HC ( <i>n</i> = 25)	0.174	0.026		
Middle Orbital Gyrus (MiOG)	Left	SZ ( <i>n</i> = 24)	0.466	0.036	3.95	0.0003**
		HC ( <i>n</i> = 25)	0.520	0.056		
	Right	SZ ( <i>n</i> = 24)	0.445	0.046	3.40	0.0014**
		HC ( <i>n</i> = 25)	0.495	0.056		
Lateral Orbital Gyrus (LOG)	Left	SZ ( <i>n</i> = 24)	0.050	0.015	0.02	0.98
		HC ( <i>n</i> = 25)	0.050	0.014		
	Right	SZ ( <i>n</i> = 24)	0.056	0.011	0.75	0.45
		HC ( <i>n</i> = 25)	0.054	0.012		

SZ = Schizophrenia; HC = Healthy control.

\**P* < 0.05, \*\**P* < 0.01.

### MiOG probability map comparison

To explore whether any region within the MiOG ROI was predominantly affected, MiOG spatially normalized probability maps were compared between the groups in common space. Figure 5 shows the *t* map of the control minus schizophrenia group differences (HC > schizophrenia). The left anterior part of MiOG (area 11) was significantly different between the groups ( $t_{46} = 4.38$ ,  $P < 0.0001$ ). No HC < schizophrenia group difference was found.

### Neuropsychological findings

Table 4 presents scores on the neuropsychological tests of interest. As can be seen in Table 4, patients showed significantly poorer performance than controls on IGT, TMT and WCST. Figure 6A shows a group difference in the IGT. The patient group showed reduced IGT performance [(C+D) – (A+B)], compared to the HC group ( $t_{47} = 2.72$ ,  $P = 0.009$ , schizophrenia:  $-3.83 \pm 27.12$ , HC:  $18.0 \pm 29.02$ ). Total amount lost was significantly larger ( $t_{47} = 2.53$ ,  $P = 0.015$ , schizophrenia:  $\$9663 \pm 1908$ , HC:  $\$8147 \pm 2267$ ), and total amount earned was significantly smaller ( $t_{47} = 2.32$ ,  $P = 0.025$ , schizophrenia:  $-\$1249 \pm 1171$ , HC:  $-\$148 \pm 2018$ ) in the schizophrenia group compared to the HC group.

Figure 6B describes gambling performance over time on task divided into five consecutive periods of 20 trials. Of note, during the first period (trials 1 to 20), the gambling score was almost same ( $t_{47} = 0.25$ ,  $P = 0.81$ ), suggesting a similar initial effect for both groups. However, the group difference in the gambling score was clear after the second to the last periods (trials 21 to 100) ( $t_{47} = 2.70$ ,  $P = 0.010$ ), with poorer performance in the schizophrenia group.

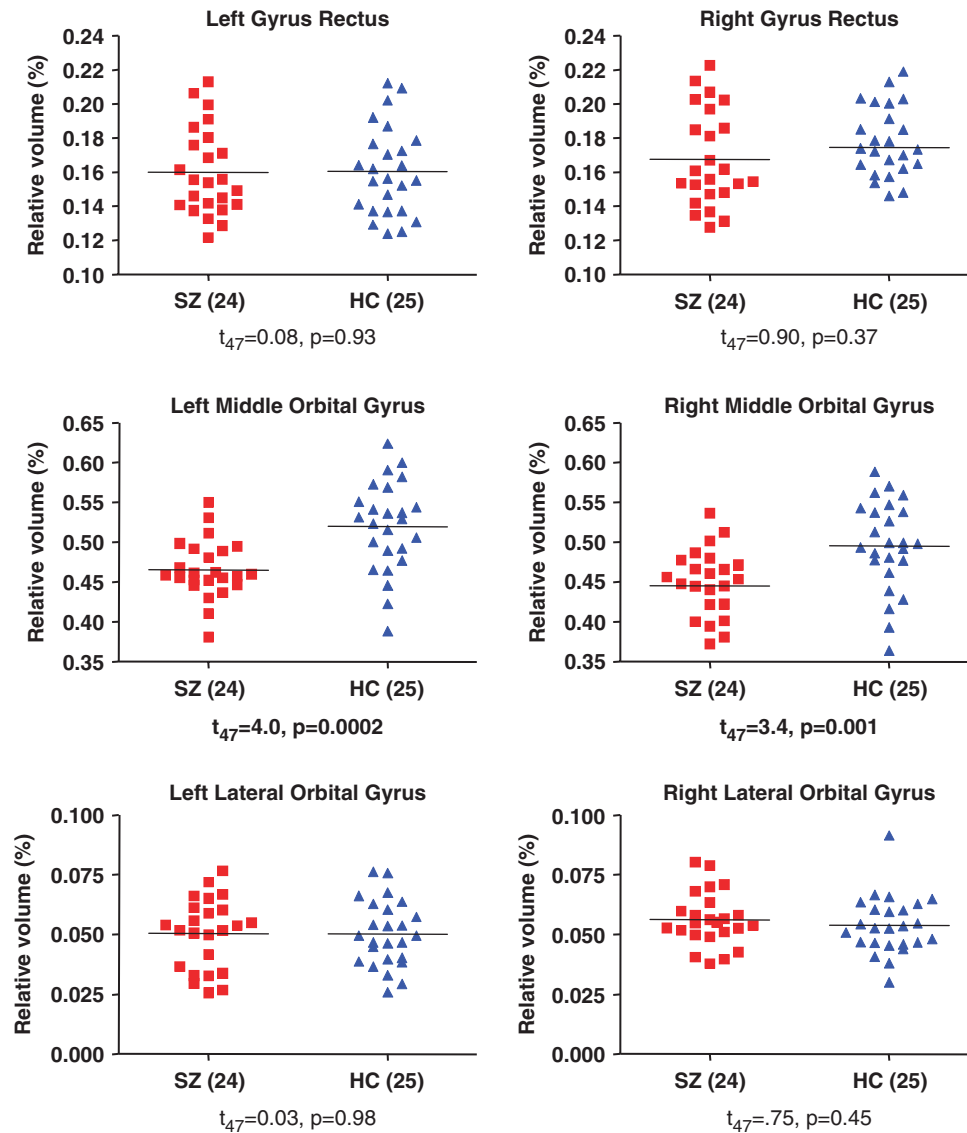
The schizophrenia group showed poorer performance than the HC group in performance speed for Trails A ( $t_{42} = 4.27$ ,  $P = 0.0001$ ) and Trails B ( $t_{42} = 3.19$ ,  $P = 0.003$ ), in number of categories completed for the WCST ( $t_{42} = 2.65$ ,  $P = 0.011$ ), as well as total number of WCST incorrect ( $t_{42} = 2.14$ ,  $P = 0.038$ ), and WCST perseverative errors ( $t_{42} = 2.85$ ,  $P = 0.007$ ). Performance in TMT and WCST was not associated with IGT performance within each group. However, the better IGT performance was associated with higher general intelligence and perceptual organization index (WAIS-III) within each group.

### Correlation analysis of OFC relative volumes

#### Patient group

The OFC volumes were not correlated with age at MRI scan, age of onset, parental and subject's SES and IQ.





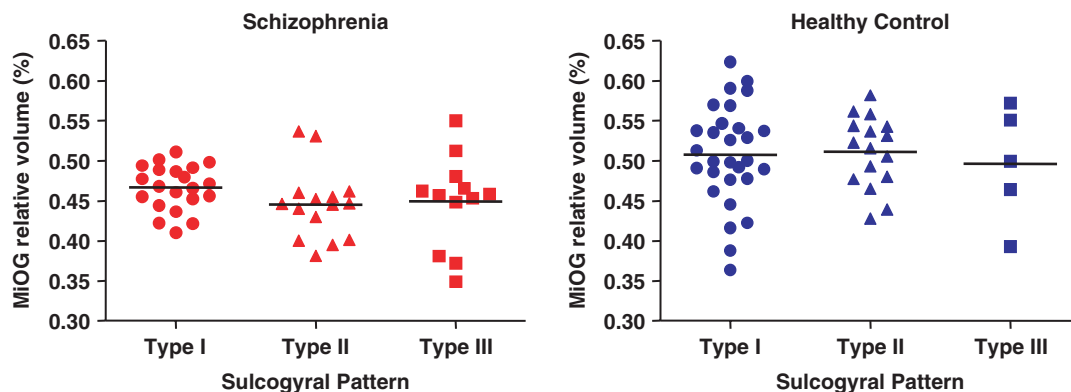
**Fig. 3** OFC volume comparison. Relative Volume = [Absolute Volume ( $\text{cm}^3$ )/Intra-Cranial Contents Volume ( $\text{cm}^3$ )]  $\times$  100 (%). Bars indicate means. Probabilities are from independent-samples  $t$ -tests. Note bilateral MiOG differences. Abbreviations: SZ = schizophrenia; HC = healthy control.

Of note, antipsychotic daily dosage, chlorpromazine equivalent, did not correlate with any OFC volume, even with oral dose normalized for brain size (ICC volumes). Also, the OFC volumes were not associated with any cognitive measures including the IGT. However, right MiOG volume was negatively correlated with illness duration (beginning at first hospitalization ( $r = -0.618$ ,  $P = 0.002$ ,  $n = 22$ , Fig. 7), the longer the illness, the smaller the right MiOG volume. In terms of clinical symptoms, left MiOG volume was negatively correlated with sum of SAPS items of ‘positive formal thought disorder’ ( $r = -0.638$ ,  $P = 0.001$ ,  $n = 23$ , Fig. 6). The smaller the left MiOG volume, the more severe the positive formal thought disorder. More specifically, four out of eight SAPS items related to the formal thought disorder showed significance below the designated alpha level

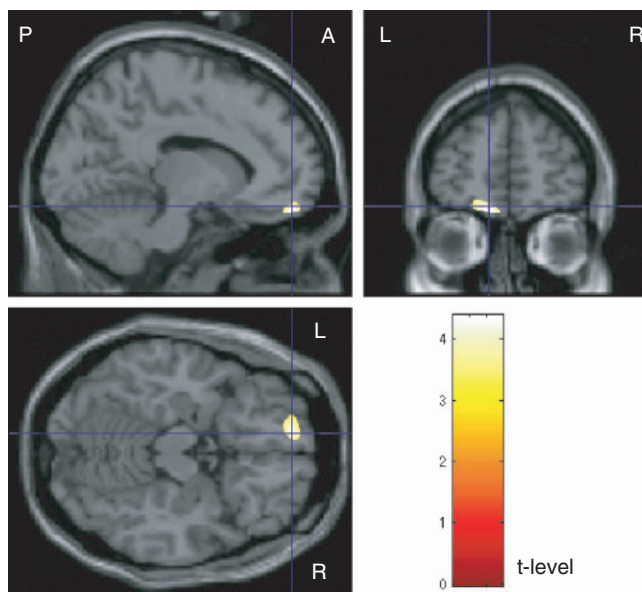
(.01): ‘circumstantiality’ ( $r = -0.624$ ,  $P = 0.001$ ,  $n = 23$ ); ‘tangentiality’ ( $r = -0.620$ ,  $P = 0.002$ ,  $n = 23$ ); ‘distractive speech’ ( $r = -0.555$ ,  $P = 0.006$ ,  $n = 23$ ); and ‘incoherence’ ( $r = -0.538$ ,  $P = 0.008$ ,  $n = 23$ ).

#### HC group

Within the HC group, the OFC volumes were not correlated with age at MRI scan, and parental and subject’s SES. In terms of cognition associations, right MiOG volume was positively correlated with WAIS-III measures of full-scale IQ ( $r = 0.610$ ,  $P = 0.002$ ,  $n = 23$ , Fig. 7), verbal comprehension index ( $r = 0.561$ ,  $P = 0.005$ ,  $n = 23$ ), and perceptual organization index ( $r = 0.605$ ,  $P = 0.002$ ,  $n = 23$ ), the larger the right MiOG volume, the better the cognitive performance. Left MiOG volume was negatively correlated



**Fig. 4** MiOG volume and sulcogyral pattern. Middle Orbital Gyri (MiOG) volumes are not different among the three sulcogyral patterns within each group.



**Fig. 5** MiOG probability map comparison. Probability maps of the Middle Orbital Gyri (MiOG) are compared between the schizophrenia and HC groups. The *t*-map indicates where *t*-level of schizophrenia < HC at the  $P < 0.0001$  level ( $t_{46} = 4.38$ ). The left anterior OFC (area II) shows a robust group difference.

with time spent in Trails B ( $r = -0.608$ ,  $P = 0.003$ ,  $n = 21$ ). In terms of the IGT (Fig. 7), right MiOG volume was positively correlated with total gambling score [(C+D) – (A+B)] ( $r = 0.541$ ,  $P = 0.005$ ,  $n = 25$ ), with gambling score [(C+D) – (A+B)] during the final period (trials 81–100) ( $r = 0.612$ ,  $P = 0.001$ ,  $n = 25$ ) and negatively correlated with total amount lost ( $r = -0.532$ ,  $P = 0.006$ ,  $n = 25$ ). These correlations suggest that the larger the right MiOG volume, the better the gambling performance as measured by appropriate evaluation of abstract reinforcers and subsequent decision-making. In contrast, WCST performance was not associated with the OFC volumes, possibly reflecting regional specificity.

In order to minimize effects from potential outliers, Spearman's rank order correlation analyses were also performed. These showed statistical significance below the designated alpha (0.01) in all of the above correlations, except for verbal comprehension index ( $\rho = 0.518$ ,  $P = 0.011$ ,  $n = 23$ ) in WAIS-III and total amount lost ( $\rho = -0.454$ ,  $P = 0.023$ ,  $n = 25$ ) in IGT.

To partial out the general intelligence effect on association between the right MiOG volume and IGT performance, partial correlations were calculated entering full-scale IQ, verbal comprehension index and perceptual organization index as controlling variables. The right MiOG volume was still positively correlated with the total gambling score ( $r = 0.492$ ,  $P = 0.028$ ,  $df = 18$ ), and negatively correlated with the total amount lost ( $r = -0.504$ ,  $P = 0.023$ ,  $df = 18$ ). These results suggest that the right MiOG–IGT association was independent of general intelligence.

## Discussion

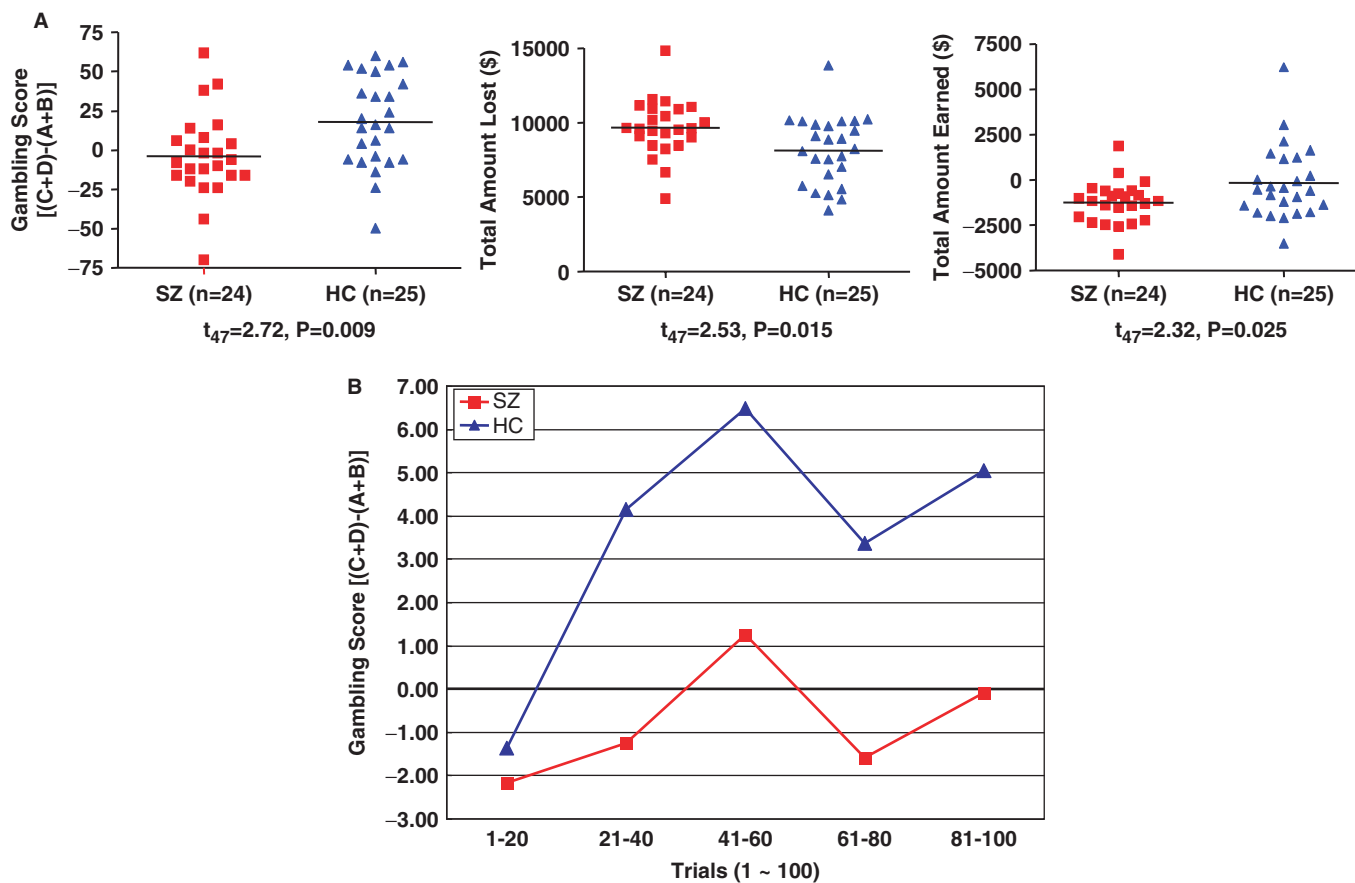
The present study introduced a new parcellation method of the OFC, one largely based on sulcal information. The parcellation of OFC into three subregions revealed regionally specific patterns of OFC volume deficit in schizophrenia, with a smaller MiOG volume in schizophrenia, one not associated with the OFC sulcogyral pattern, although the pattern differed in the two groups. Additionally, within the smaller MiOG of the schizophrenia group, a VBM analysis of probability maps indicated the left anterior MiOG (area II) was most robustly decreased compared to control group. We note here that, although left and right MiOG volumes clearly showed marked group differences, these differences were not sufficient to be diagnostic of schizophrenia. Smaller right MiOG volumes within the schizophrenia group were associated with a longer duration of illness, while a smaller left MiOG volume was associated with more severe positive formal thought disorder symptoms. Within the HC group, larger

**Table 4** Descriptive data in neuropsychological examinations

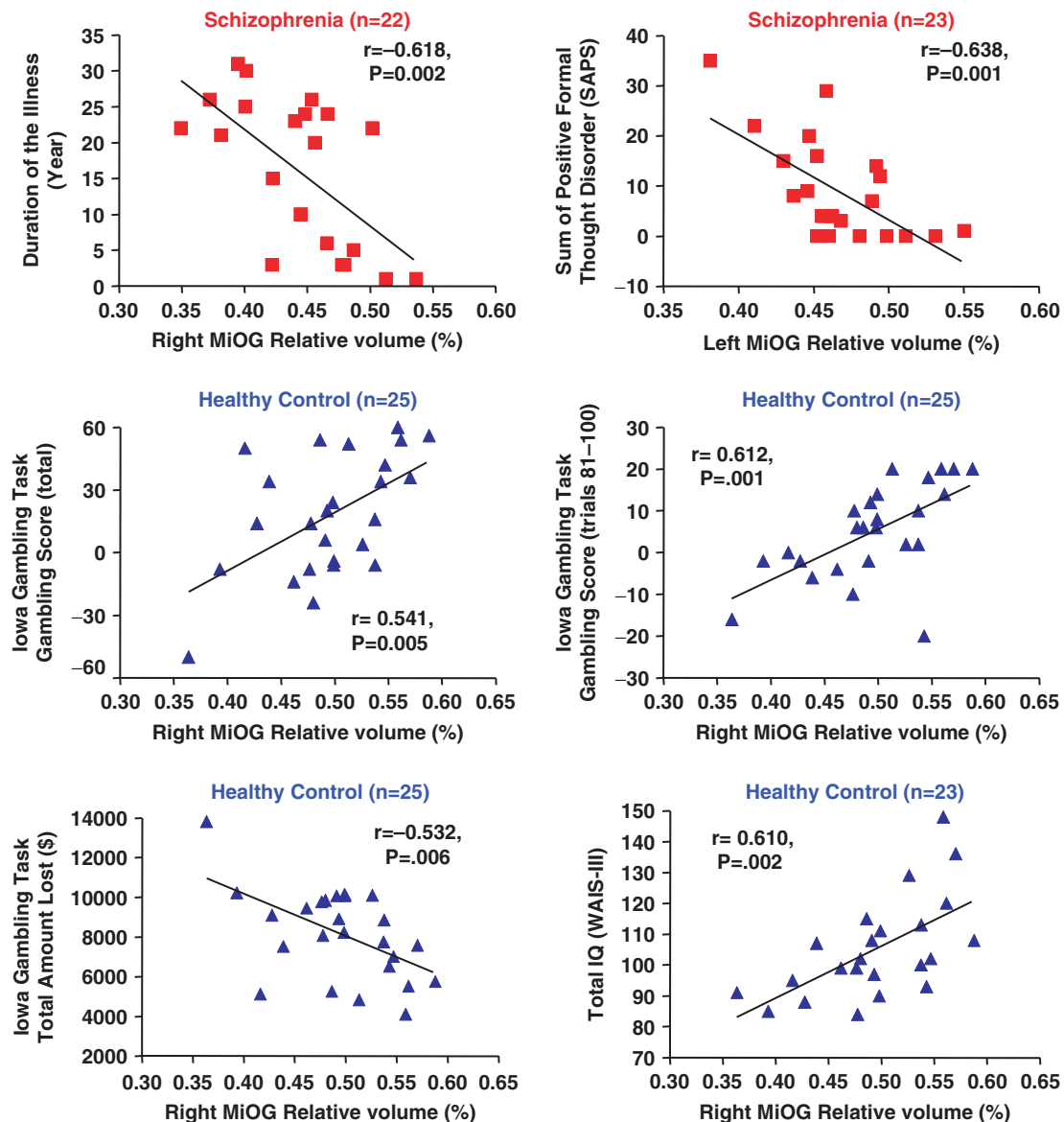
Test/Variable	Mean (SD)		df <sup>a</sup>	t-test	P-value
	Schizophrenic patients	Healthy control subjects			
<b>Iowa gambling task (IGT)</b>					
Total gambling score (Trials: 1–100)	-3.83 (27.12)	18.00 (29.02)	1, 47	2.72	0.009**
Gambling score (Trials: 81–100)	-0.08 (9.16)	5.04 (11.22)	1, 47	1.75	0.087
Total amount lost (\$)	9663.5 (1908.7)	8147.0 (2267.6)	1, 47	2.53	0.015*
Total amount earned (\$)	-1249.8 (1171.8)	-148.2 (2018.6)	1, 47	2.32	0.025*
<b>Trail making test (TMT)</b>					
Trail A time spent (s)	46.61 (16.12)	29.92 (8.36)	1, 42	4.27	0.0001**
Trail A errors made	0.21 (0.42)	0.14 (0.36)	1, 42	0.56	0.58
Trail B time spent (s)	113.81 (62.10)	69.10 (17.40)	1, 42	3.19	0.003**
Trail B errors made	1.61 (3.75)	0.29 (0.64)	1, 42	1.59	0.12
<b>Wisconsin card sorting test (WCST)</b>					
Number of categories completed	3.50 (2.44)	5.14 (1.55)	1, 42	2.65	0.011*
Total number incorrect	44.36 (29.63)	27.18 (23.27)	1, 42	2.14	0.038*
Perseverative errors	27.45 (23.82)	12.18 (8.13)	1, 42	2.85	0.007**
Non-perseverative errors	16.91 (10.59)	15.00 (16.19)	1, 42	0.46	0.65

<sup>a</sup>The df differ among variables owing to unavailability of data in some participants.

\* $P < 0.05$ , \*\* $P < 0.01$ .



**Fig. 6** Iowa Gambling Task. Panel A. The schizophrenia group (SZ, red squares) shows poorer performance in Iowa Gambling Task (IGT) as compared to healthy control group (HC, blue triangles). Panel B. IGT performance over time divided into five periods of consecutive 20 trials. At trials 1–20, the gambling scores are almost the same, while groups clearly differ in the gambling score thereafter (trials 21 to 100) with poorer performance in the SZ group.



**Fig. 7** Clinical/cognitive correlation analysis. In the schizophrenia group (red squares), smaller left MiOG volumes are associated with more severe positive formal thought disorder. Longer duration of the illness from the first hospitalization for psychosis is associated with smaller MiOG volume. In the control group (blue triangles), larger right MiOG volumes are independently associated with better performance in Iowa Gambling Task and higher IQ.

right MiOG volume was associated with better performance in the IGT, as well as higher general intelligence, independently. To our knowledge, this is the first report of a significant association between OFC volume and IGT performance.

Most of the previous OFC volumetry defined the OFC as a single ROI covering the entire ventral prefrontal surface, while some others (Crespo-Facorro *et al.*, 1999; Lacerda *et al.*, 2003; Ballmaier *et al.*, 2004) divided the OFC region into GR and other orbitofrontal region using the olfactory sulcus, the clearest orbitofrontal sulcus, as a boundary sulcus. The present parcellation approach made each OFC ROI less heterogeneous in terms of cytoarchitecture

(Ongur *et al.*, 2003), compared to a single ROI covering the entire ventral prefrontal surface. For example, our LOG ROI exclusively contained a part of area 47 and our MiOG ROI successfully excluded most parts of area 10 including area 11 and area 13. To address the ambiguity of the lateral boundary issue, a highly geometric method has been previously applied in order to evaluate the OFC volume (Lacerda *et al.*, 2003). Although, this geometric method yielded a very high inter-rater reliability of more than 0.99, intuitively, it seems not to be as sensitive to inter-individual anatomical variation as is our own approach. Furthermore, their OFC ROI definition did not include most of area 47 but did include inferior part of frontopolar gyri (area 10)

and part of medial wall area of prefrontal cortex, structures that are considered to be outside of the OFC.

To explore the significance of the MiOG volume deficit observed in the schizophrenia group further, we examined other factors, which might be associated with MiOG volume. We previously reported a sulcogyral pattern alteration in the ‘H-shaped’ sulcus in schizophrenic subjects (Nakamura *et al.*, 2007). In the present dataset, the alteration in the sulcogyral pattern distribution was replicated in the schizophrenia group, possibly reflecting neurodevelopmental alteration or susceptibility to schizophrenia. However, this sulcogyral pattern was not associated with the MiOG volume, indicating that the regional grey matter volume deficit and its sulcogyral pattern alteration were independent. We did find the least common Type III sulcogyral expression, increased in the schizophrenia group, to be associated with a lack of the normal asymmetry in GR volume and smaller ICC volume, suggesting that the Type III expression may reflect a subgroup of schizophrenia patients characterized by more severe neurodevelopmental aberrations than patients without Type III. Although the smaller right MiOG volume was not associated with the patients’ age at MRI scan or chlorpromazine-equivalent antipsychotic dosage, the longer the duration of the illness (starting from first hospitalization for psychosis) the smaller the MiOG. Although a longitudinal study will be needed for definitive conclusions, this finding would be compatible with a post-onset, time-dependent progression of volume loss or medication-related volume loss.

In terms of clinical and cognitive associations with OFC volume in the previous studies on schizophrenia, a smaller OFC volume was associated with more severe negative symptoms (Baare *et al.*, 1999; Gur *et al.*, 2000), social dysfunction (Gur *et al.*, 2000; Chemerinski *et al.*, 2002) and poor insight (Sapara *et al.*, 2007). In contrast, a larger OFC volume was associated with a greater level of aggression (Hoptman *et al.*, 2005) and more severe negative symptom (Lacerda *et al.*, 2007). Cognitive associations with OFC grey matter volume in schizophrenia have been reported in but a single paper (Hoptman *et al.*, 2005), with larger right OFC grey matter volume associated with poorer performance in the TMT.

Of particular note, the smaller left MiOG volume observed in the schizophrenia group was strongly associated with more severe positive formal thought disorder as measured by SAPS, especially in ‘circumstantiality’, ‘tangentiality’, ‘distractive speech’ and ‘incoherence’. We speculate these features associated with left MiOG volume could reflect a milder form of suppression failure of evoked memory traces irrelevant to ongoing reality similar to ‘spontaneous confabulations’ as described in non-psychiatric patients with OFC lesions (Schnider, 2003). Schizophrenic patients with smaller MiOG volume could have more difficulty in monitoring ongoing reality in speech; in other words, it could be difficult for them to

monitor their previous speech and properly adapt the ongoing speech to what had gone before, suppressing irrelevant activations from memory. This might result in enhanced ‘circumstantiality’, ‘tangentiality’, ‘distractive speech’ and ‘incoherence’.

How might this left MiOG association with formal thought disorder be related to our previously reported association between left Superior Temporal Gyrus (STG) volume and the degree of formal thought disorder, as assessed by the Johnston-Holzman measures (Shenton *et al.*, 1992)? Recent brain stimulation studies in awake individuals during brain tumour surgery showed that left inferior occipitofrontal fasciculus (IOFF) stimulation induced semantic paraphasia while left arcuate fasciculus stimulation induced phonological paraphasia (Duffau *et al.*, 2005; Mandonnet *et al.*, 2007). The authors proposed this IOFF-mediated dominant hemisphere neuronal circuit constitutes a ‘semantic ventral stream’, one indispensable for semantic processing and linking language-related temporal cortical regions (including STG) with frontal lobe. Indeed, in schizophrenia, our fiber tractography study has revealed white matter abnormalities in the IOFF (Kubicki *et al.*, 2006). Combining these findings, we suggest altered neuronal interaction between left OFC and left posterior temporal region via IOFF could be a critical neuronal circuit for formal thought disorder in schizophrenia. Supporting this model, studies in our lab have found schizophrenics showed abnormally enhanced activation of the STG in semantic encoding (Kubicki *et al.*, 2003) and decreased left inferior prefrontal cortex activation. This abnormally enhanced activation could interact with an OFC failure of suppression of unrelated associations. Clinically, evaluation of patients with IOFF lesions in a dominant hemisphere becomes very interesting in terms of effects of disruption of the proposed neuronal circuit model on formal thought disorder.

On the IGT, the present schizophrenia group demonstrated poorer performance as compared with the HC group. The time course of the gambling score (Fig. 6b) was markedly contrasting between the groups, and the deficit pattern we found in the schizophrenia group was similar to that reported in patients with ventromedial prefrontal lesions (Bechara *et al.*, 2000). However, IGT performance in studies of schizophrenic subjects has been inconsistent; some of the previous studies reported poorer performance in schizophrenic subjects (Beninger *et al.*, 2003; Ritter *et al.*, 2004; Bark *et al.*, 2005; Shurman *et al.*, 2005), consistent with the present results, while some others reported negative findings (Wilder *et al.*, 1998; Cavallaro *et al.*, 2003; Rodriguez-Sanchez *et al.*, 2005).

The present chronic schizophrenia group had both smaller MiOG volume and poorer IGT performance than the HC group, however, in schizophrenics, the MiOG volume was not associated with IGT performance. Interestingly, the larger MiOG volume was associated with better IGT performance within the HC group, independent

of general intelligence. Of note, WCST performance was not associated with OFC volumes or IGT performance. This specific biological association between MiOG volume and IGT performance may reflect normal variability in the decision-making process consequent to OFC structural variability, and is supportive of the validity of our present OFC ROI definitions. Milad *et al.* (2005) reported quantitative anatomical–functional association in medial OFC between cortical thickness and fear extinction memory in healthy subjects. The present HC subject finding would add another anatomically based substrate of OFC functional variation among healthy individuals. Within the patient group, disease-related factors such as duration of the illness or the usage of psychotropics might confound the measurement of OFC volume, making it difficult to detect the same association that we observed in the HC group.

Group comparisons in MiOG probability maps suggested that the morphological alteration in MiOG of schizophrenic patients is stronger in anterior heteromodal (neocortical) region than in posterior paralimbic region. This contrast may account for poorer patient group performance of IGT, which is related to abstract reward evaluation. Also, this finding would be compatible with the hypothesis of heteromodal association cortices as a major site of abnormalities in schizophrenia (Ross and Pearlson, 1996).

As a methodological limitation of the present study, we note that gender frequency was not matched between the two study groups and the schizophrenia group included only males. Thus, it was impossible to control for gender in volume comparison and also to investigate OFC sexual dimorphism. Future studies with larger samples including both genders are needed.

In conclusion, the present study applied a new anatomically based OFC parcellation and revealed a subregion-specific pattern of OFC volume deficit in schizophrenia. The OFC volume deficit was associated with longer duration of illness and more severe positive formal thought disorder but not with OFC sulcogyral pattern. The schizophrenia group exhibited poorer performance in the IGT, but OFC volume was not correlated with IGT performance. In contrast, the HC group showed a quantitative association between right MiOG volume and IGT performance.

### Supplementary material

Supplementary material is available at *Brain* online.

### Acknowledgements

This study was supported, in part, by the Department of Veterans Affairs Merit Awards (MES, RWM), a Research Enhancement Award Program (RWM, MES), a Schizophrenia Center (RWM, MES) and a Middleton Award (RWM)

from the Department of Veterans Affairs, grants from the National Institute of Health (K02 MH 01110 and R01 MH 50747 to MES, R01 MH 40799 to RWM), the MIND foundation (Albuquerque, NM, RWM), and the Wellfide Medicinal Research Foundation, Japan (MN). Some of the data were presented at annual meetings of Biological Psychiatry, Toronto, Ontario, May 19, 2006, and of Organization of Human Brain Mapping, Florence, Italy, 11–15 June 2006. The authors gratefully acknowledge helpful comments from Marek Kubicki, M.D., Ph.D., the administrative support of Marie Fairbanks and Nancy Maxwell, the technical support of Hae-Jeong Park, Ph.D., and the research assistant support of Lisa Lucia, B.A., Matthew Koskowski, B.A., Elizabeth Lewis, B.A. and Lillian Hsu, B.A.

### References

- Andreasen NC. Scale for the assessment of negative symptoms (SANS). Department of psychiatry. Iowa City, IA: University of Iowa College of medicine; 1981.
- Andreasen NC. Scale for the assessment of positive symptoms (SAPS). Department of psychiatry. Iowa City, IA: University of Iowa College of medicine; 1984.
- Armstrong E, Schleicher A, Omran H, Curtis M, Zilles K. The ontogeny of human gyrification. *Cereb Cortex* 1995; 5: 56–63.
- Ashburner J, Friston KJ. Voxel-based morphometry—the methods. *Neuroimage* 2000; 11: 805–21.
- Baare WF, Hulshoff Pol HE, Hijman R, Mali WP, Viergever MA, Kahn RS. Volumetric analysis of frontal lobe regions in schizophrenia: relation to cognitive function and symptomatology. *Biol Psychiatr* 1999; 45: 1597–605.
- Ballmaier M, Toga AW, Blanton RE, Sowell ER, Lavretsky H, Peterson J, et al. Anterior cingulate, gyrus rectus, and orbitofrontal abnormalities in elderly depressed patients: an MRI-based parcellation of the prefrontal cortex. *Am J Psychiatr* 2004; 161: 99–108.
- Barbas H, Pandya DN. Architecture and intrinsic connections of the prefrontal cortex in the rhesus monkey. *J Comp Neurol* 1989; 286: 353–75.
- Bark R, Dieckmann S, Bogerts B, Northoff G. Deficit in decision making in catatonic schizophrenia: an exploratory study. *Psychiatry Res* 2005; 134: 131–41.
- Bechara A, Damasio AR, Damasio H, Anderson SW. Insensitivity to future consequences following damage to human prefrontal cortex. *Cognition* 1994; 50: 7–15.
- Bechara A, Damasio H, Tranel D, Anderson SW. Dissociation Of working memory from decision making within the human prefrontal cortex. *J Neurosci* 1998; 18: 428–37.
- Bechara A, Tranel D, Damasio H. Characterization of the decision-making deficit of patients with ventromedial prefrontal cortex lesions. *Brain* 2000; 123 (Pt 11): 2189–202.
- Beck E. A cytoarchitectural investigation into the boundaries of cortical areas 13 and 14 in the human brain. *J Anat* 1949; 83: 147–57.
- Beninger RJ, Wasserman J, Zanibbi K, Charbonneau D, Mangels J, Beninger BV. Typical and atypical antipsychotic medications differentially affect two nondeclarative memory tasks in schizophrenic patients: a double dissociation. *Schizophr Res* 2003; 61: 281–92.
- Bouix S, Martin-Fernandez M, Ungar L, Nakamura M, Koo MS, McCarley RW, et al. On evaluating brain tissue classifiers without a ground truth. *Neuroimage* 2007; 36: 1207–1224.
- Carmichael ST, Price JL. Connectional networks within the orbital and medial prefrontal cortex of macaque monkeys. *J Comp Neurol* 1996; 371: 179–207.

- Cavallaro R, Cavedini P, Mistretta P, Bassi T, Angelone SM, Ubbiali A, et al. Basal-cortico-frontal circuits in schizophrenia and obsessive-compulsive disorder: a controlled, double dissociation study. *Biol Psychiatr* 2003; 54: 437–43.
- Chemerinski E, Nopoulos PC, Crespo-Facorro B, Andreasen NC, Magnotta V. Morphology of the ventral frontal cortex in schizophrenia: relationship with social dysfunction. *Biol Psychiatr* 2002; 52: 1–8.
- Chiavaras MM, Petrides M. Orbitofrontal sulci of the human and macaque monkey brain. *J Comp Neurol* 2000; 422: 35–54.
- Convit A, Wolf OT, de Leon MJ, Patalinjug M, Kandil E, Caraos C, et al. Volumetric analysis of the pre-frontal regions: findings in aging and schizophrenia. *Psychiatry Res* 2001; 107: 61–73.
- Crespo-Facorro B, Kim JJ, Andreasen NC, O'Leary DS, Wiser AK, Bailey JM, et al. Human frontal cortex: an MRI-based parcellation method. *Neuroimage* 1999; 10: 500–19.
- Cummings JL. Frontal-subcortical circuits and human behavior. *Arch Neurol* 1993; 50: 873–80.
- Duffau H, Gatignol P, Mandonnet E, Peruzzi P, Tzourio-Mazoyer N, Capelle L. New insights into the anatomo-functional connectivity of the semantic system: a study using cortico-subcortical electrostimulations. *Brain* 2005; 128: 797–810.
- Duvernoy HM. The human brain: surface, three-dimensional sectional anatomy with MRI, and blood supply. New York, NY: Springer-Verlag Wien; 1999.
- Fuster JM. The prefrontal cortex: anatomy, physiology, and neuropsychology of the frontal lobe. Philadelphia, PA: Lippincott-Raven; 1997.
- Good CD, Johnsrude IS, Ashburner J, Henson RN, Friston KJ, Frackowiak RS. A voxel-based morphometric study of ageing in 465 normal adult human brains. *Neuroimage* 2001; 14: 21–36.
- Gottfried JA, O'Doherty J, Dolan RJ. Encoding predictive reward value in human amygdala and orbitofrontal cortex. *Science* 2003; 301: 1104–7.
- Gur RE, Cowell PE, Latshaw A, Turetsky BI, Grossman RI, Arnold SE, et al. Reduced dorsal and orbital prefrontal gray matter volumes in schizophrenia. *Arch Gen Psychiatr* 2000; 57: 761–8.
- Gurling HM, Critchley H, Datta SR, McQuillin A, Blaveri E, Thirumalai S, et al. Genetic association and brain morphology studies and the chromosome 8p22 pericentriolar material 1 (PCM1) gene in susceptibility to schizophrenia. *Arch Gen Psychiatr* 2006; 63: 844–54.
- Harlow JM. Passage of an iron rod through the head. *Boston Med Surg J* 1848; 39: 389–93.
- Heaton RK. Wisconsin Card Sorting Test, Manual. Odessa, FL: Psychological Assessment Resources; 1981.
- Holland PC, Gallagher M. Amygdala-frontal interactions and reward expectancy. *Curr Opin Neurobiol* 2004; 14: 148–55.
- Hollingshead A. Two factor index of social position. New Haven, CT: Yale University Press; 1965.
- Honea R, Crow TJ, Passingham D, Mackay CE. Regional deficits in brain volume in schizophrenia: a meta-analysis of voxel-based morphometry studies. *Am J Psychiatr* 2005; 162: 2233–45.
- Hoptman MJ, Volavka J, Weiss EM, Czobor P, Szeszko PR, Gerig G, et al. Quantitative MRI measures of orbitofrontal cortex in patients with chronic schizophrenia or schizoaffective disorder. *Psychiatry Res* 2005; 140: 133–45.
- Hulshoff Pol HE, Schnack HG, Mandl RC, Brans RG, van Haren NE, Baare WF, et al. Gray and white matter density changes in monozygotic and same-sex dizygotic twins discordant for schizophrenia using voxel-based morphometry. *Neuroimage* 2006; 31: 482–8.
- Kay SR, Fiszbein A, Opler LA. The positive and negative syndrome scale (PANSS) for schizophrenia. *Schizophr Bull* 1987; 13: 261–76.
- Kringelbach ML. The human orbitofrontal cortex: linking reward to hedonic experience. *Nat Rev Neurosci* 2005; 6: 691–702.
- Kubicki M, Bushnell GB, Markant D, Dreusicke MH, Park HJ, Bouix S, et al. In vivo diffusion fiber tractography suggests disruptions in connectivity between the frontal and temporal lobes in schizophrenia. *Sixty First Annual Meeting of Society of Biological Psychiatry* Toronto, Canada; 2006.
- Kubicki M, McCarley RW, Nestor PG, Huh T, Kikinis R, Shenton ME, et al. An fMRI study of semantic processing in men with schizophrenia. *Neuroimage* 2003; 20: 1923–33.
- Lacerda AL, Hardan AY, Yorbik O, Keshavan MS. Measurement of the orbitofrontal cortex: a validation study of a new method. *Neuroimage* 2003; 19: 665–73.
- Lacerda AL, Hardan AY, Yorbik O, Vemulapalli M, Prasad KM, Keshavan MS. Morphology of the orbitofrontal cortex in first-episode schizophrenia: relationship with negative symptomatology. *Prog Neuropsychopharmacol Biol Psychiatr* 2007; 31: 510–6.
- Mandonnet E, Nouet A, Gatignol P, Capelle L, Duffau H. Does the left inferior longitudinal fasciculus play a role in language? A brain stimulation study. *Brain* 2007; 130: 623–9.
- Mesulam MM. Principles of behavioral and cognitive neurology. Philadelphia: F.A. Davis; 1985.
- Milad MR, Quinn BT, Pitman RK, Orr SP, Fischl B, Rauch SL. Thickness of ventromedial prefrontal cortex in humans is correlated with extinction memory. *Proc Natl Acad Sci USA* 2005; 102: 10706–11.
- Nakamura M, Nestor PG, McCarley RW, Levitt JJ, Hsu L, Kawashima T, et al. Altered orbitofrontal sulcogyral pattern in schizophrenia. *Brain* 2007; 130: 693–707.
- Oldfield RC. The assessment and analysis of handedness: the Edinburgh inventory. *Neuropsychologia* 1971; 9: 97–113.
- Ongur D, Ferry AT, Price JL. Architectonic subdivision of the human orbital and medial prefrontal cortex. *J Comp Neurol* 2003; 460: 425–49.
- Ongur D, Price JL. The organization of networks within the orbital and medial prefrontal cortex of rats, monkeys and humans. *Cereb Cortex* 2000; 10: 206–19.
- Ono M, Kubik S, Abernathy CD. Atlas of the cerebral sulci. New York, NY: Thieme Medical Publishers; 1990.
- Pohl KM, Bouix S, Nakamura M, Rohlfing T, McCarley RW, Kikinis R, et al. A hierarchical algorithm for MR brain image parcellation. *IEEE T Med Imaging* 2007; 26: 1201–12.
- Rakic P. Specification of cerebral cortical areas. *Science* 1988; 241: 170–6.
- Reitan RM. Validity of the Trail Making Test as an indication of organic brain damage. *Perceptual Motor Skills* 1958; 8: 271.
- Ritter LM, Meador-Woodruff JH, Dalack GW. Neurocognitive measures of prefrontal cortical dysfunction in schizophrenia. *Schizophr Res* 2004; 68: 65–73.
- Rodriguez-Sanchez JM, Crespo-Facorro B, Iglesias RP, Bosch CG, Alvarez M, Llorca J, et al. Prefrontal cognitive functions in stabilized first-episode patients with schizophrenia spectrum disorders: a dissociation between dorsolateral and orbitofrontal functioning. *Schizophr Res* 2005; 77: 279–88.
- Ross CA, Pearlson GD. Schizophrenia, the heteromodal association neocortex and development: potential for a neurogenetic approach. *Trends Neurosci* 1996; 19: 171–6.
- Rupp CI, Fleischhacker WW, Kemmler G, Kremser C, Bilder RM, Mechtcheriakov S, et al. Olfactory functions and volumetric measures of orbitofrontal and limbic regions in schizophrenia. *Schizophr Res* 2005; 74: 149–61.
- Sapara A, Cooke M, Fannon D, Francis A, Buchanan RW, Anilkumar AP, et al. Prefrontal cortex and insight in schizophrenia: a volumetric MRI study. *Schizophr Res* 2007; 89: 22–34.
- Schnider A. Spontaneous confabulation and the adaptation of thought to ongoing reality. *Nat Rev Neurosci* 2003; 4: 662–71.
- Shenton ME, Kikinis R, Jolesz FA, Pollak SD, LeMay M, Wible CG, et al. Abnormalities of the left temporal lobe and thought disorder in schizophrenia. A quantitative magnetic resonance imaging study. *N Engl J Med* 1992; 327: 604–12.

- Shurman B, Horan WP, Nuechterlein KH. Schizophrenia patients demonstrate a distinctive pattern of decision-making impairment on the Iowa Gambling Task. *Schizophr Res* 2005; 72: 215–24.
- Spitzer RL, Williams JBW, Gibbon M, First M. The structured clinical interview for DSM-III-R-non-patient edition (SCID-NP). Washington, DC: American Psychiatric Association; 1990a.
- Spitzer RL, Williams JBW, Gibbon M, First M. The structured clinical interview for DSM-III-R (SCID). Washington, DC: American Psychiatric Association; 1990b.
- Szeszko PR, Bilder RM, Lencz T, Pollack S, Alvir JM, Ashtari M, et al. Investigation of frontal lobe subregions in first-episode schizophrenia. *Psychiatry Res* 1999; 90: 1–15.
- Walton ME, Devlin JT, Rushworth MF. Interactions between decision making and performance monitoring within prefrontal cortex. *Nat Neurosci* 2004; 7: 1259–65.
- Wechsler D. Wechsler Adult intelligence scale. 3rd edn., San Antonio, TX: Psychological Corp: Harcourt Brace Jovanovich Inc; 1997.
- Wilder KE, Weinberger DR, Goldberg TE. Operant conditioning and the orbitofrontal cortex in schizophrenic patients: unexpected evidence for intact functioning. *Schizophr Res* 1998; 30: 169–74.
- Woods SW. Chlorpromazine equivalent doses for the newer atypical antipsychotics. *J Clin Psychiatr* 2003; 64: 663–7.